All-Epiphyseal Versus Micheli-Kocher Anterior Cruciate Ligament Reconstruction in Skeletally Immature Patients: A Systematic Review

Alexander Zakharia, Fares Al-Katanani, Ahmed Hatem, Saihaj Dhillon, Prushoth Vivekanantha, Dan Cohen, Darren de SA

McMaster Sports Research Group, Division of Orthopedic Surgery, McMaster University, Hamilton, Ontario

Introduction

Pediatric anterior cruciate ligament reconstruction (ACLR) is increasing in incidence[1]

Delaying pediatric ACLR due to physis closure may be associated with chronic instability, and progressively worse chondral damage[2]

All-epiphyseal (AE) ACLR techniques have been defined as placing the graft, tunnels, and fixation in the epiphysis sparing the physis[3]

The Micheli-Kocher (MK) ACLR technique combines intra-articular and extra-articular reconstruction with an iliotibial band (ITB) autograft, passed "over-the-top" of the lateral femoral condyle and then sutured down to the origin[4]

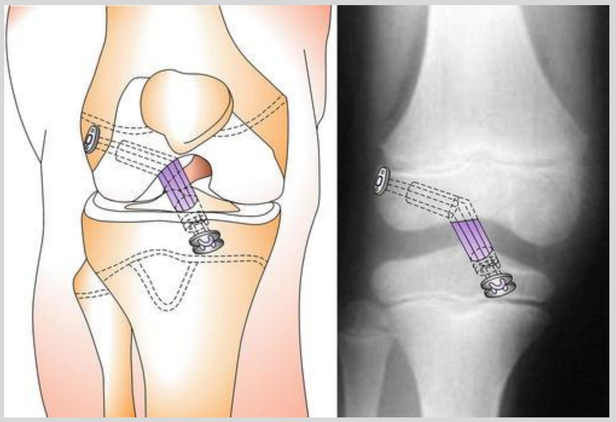

Primary Objective

1) The purpose of this review is to comprehensively compare postoperative outcomes and complication profiles following AE and MK ACLR in skeletally immature patients

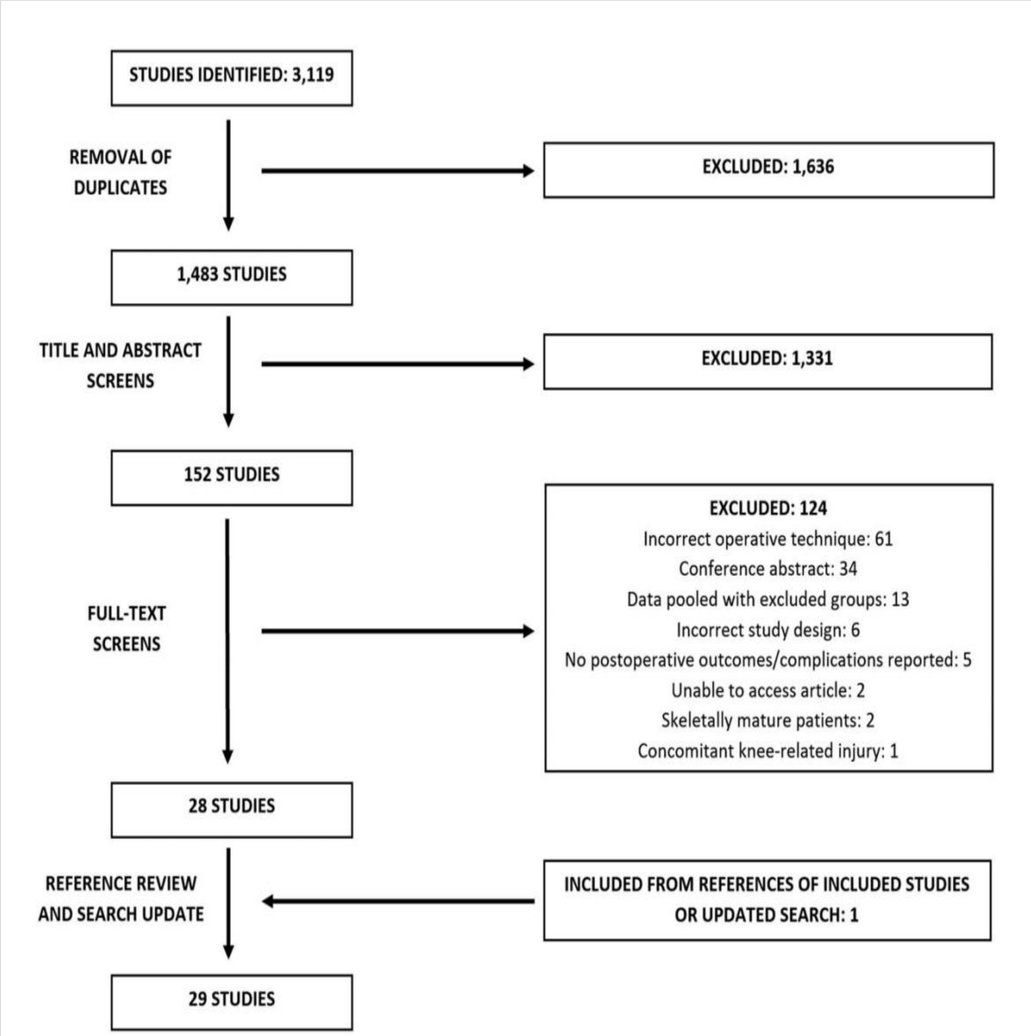

Methods

Three databases (PubMed, MEDLINE, EMBASE) were searched on January 8, 2024

Outcomes included:

- Pivot-shift and Lachman tests
- Pediatric International Knee Documentation Committee (Pedi-IKDC)
- Graft failure, growth disturbances, complication rates
- Return to sport (RTS)

Methodological quality was assessed with the MINORS scale

Data was reported in descriptive fashion

Demographic Results

Twenty-nine studies were included, 1,177 total patients (1,182 knees)

AE ACLR: 749 patients (750 knees), mean age (SD): 12.1 (1.8) years, 30.2% female, 93% receiving hamstring tendon autograft, 5.9% receiving allograft, 1.5% hybrid graft, 0.2% quadriceps tendon autograft, follow-up time ranged from 6-43.2 months postoperatively

MK ACLR: 428 patients (432 knees), mean age (SD): 11.6 (1.9) years, 13.7% female, follow-up time ranged from 6-63.6 months postoperatively

Outcomes

AE and MK ACLR resulted in similar rates of return to pre-injury level of activity (91.8% and 93.4%, respectively)

AE and MK ACLR resulted in a negative pivot-shift in 93.9% and 95.2% of cases, respectively

AE and MK ACLR resulted in IKDC scores of 94.0 and 93.6, respectively

AE ACLR resulted in rates of growth disturbances, angular deformity, and graft failure of 1.5%, 1.3%, and 10.6%, respectively

MK ACLR resulted in rates of growth disturbances, angular deformity, and graft failure of 0%, 0%, and 6.6%, respectively

Discussion

AE ACLR may be associated with a clinically greater risk of postoperative growth disturbances, growth deformities and graft failure than MK ACLR

Greater risk of physeal damage may be due to thermal damage from drilling tunnels

There may be an over-constraining effect with over-the-top techniques

Conclusion

Both AE and MK ACLR yield promising rates of RTS, substantially limit anteroposterior laxity, and have good patient reported outcome measures

There is high heterogeneity in the studies included due to low level of evidence, therefore no statistical comparisons can be drawn

Disclosures

Darren de SA:
-Pendopharm Speakers Bureau
-International Quadriceps Tendon Interest Group Member
-Magellan Society Member
-Grant funding from Physician Services' Incorporated, Canadian Orthopedic Foundation, and Canadian Institutes of Health Research for the SQuASH Trial

References

1. Tepolt FA, Feldman L, Kocher MS. Trends in pediatric ACL reconstruction from the PHIS database. J Pediatr Orthop. 2018;38: e490–e494.
2. Musahl V, Diermeier T, de Sa D, Karlsson J. "ACL surgery: when to do it?". Knee Surg Sports Traumatol Arthrosc. 2020 Jul;28(7):2023-2026. doi: 10.1007/s00167-020-06117-y. Epub 2020 Jul 4. PMID: 32621042.
3. Lykissas MG, Nathan ST, Wall EJ. All-epiphyseal anterior cruciate ligament reconstruction in skeletally immature patients: a surgical technique using a split tibial tunnel. Arthrosc Tech. 2012 Jul 27;1(1):e133-9. doi: 10.1016/j.eats.2012.05.005. PMID: 23766968; PMCID: PMC3678647.
4. Kocher MS, Garg S, Micheli LJ. Physeal sparing reconstruction of the anterior cruciate ligament in skeletally immature prepubescent children and adolescents. J Bone Joint Surg Am. 2005 Nov;87(11):2371-9. doi: 10.2106/JBJS.D.02802. PMID: 16264110.